



# HAMSA HOMEOPATHY MEDICAL COLLEGE HOSPITAL & RESEARCH CENTRE

Ksheerasagar(V), Mulugu(M), Siddipet Dist., Telangana - 502279

Our students bagged the first position in the Poster Presentation Competition  
organized by the National Journal of Homeopathy



wife



I am accused !!

# " I am wrongly accused " A case of Psoriasis-evidence based study

Presenters:

A.Sarika,Maleeha,R.Anusha,B.Shivani,C.Ramya sreelekha,Ch.Venkataramani,A.preetam reddy, G.Chakravarthy, M.pallavi G.Parimala - Illrd year BHMS students

Moderator:

Dr.Maresh chevva,M.D(Hom.) HOD Dept of Repertory,

Hamsa Homoeopathy medical college,Hospital & research centre,Mulugu,Telangana

## Introduction:

Psoriasis is a chronic, inflammatory, auto-immune disorder characterised by hyperproliferation of keratinocytes of epidermis with an increase in epidermal cell turnover rate. It is an external manifestation of internal turmoil.

## Abstract:

Psoriasis is considered to be incurable as per modern science. This case is an perfect example of what homoeopathy can offer in such a psycho-somatic disorders. As per Homoeopathy mind is the key to the man. This case clearly demonstrates the complete cure when we deal with the cause of disease in patient.

## Case:

Name: Mr.B.M  
Age:44yrs  
Sex:Male  
Education: B.Tech  
Status: Divorced  
Occupation: M.D of French company  
Non vegetarian  
Address: Hyderabad  
Case defined on:7/07/2017

## Chief complaints:

Location	Sensation	Modalities	Concomitants
Skin Since 2010 started in Lower limbs	Erythematous eruptions+++ Scaling++	< same whole through out the year.	
Chest area Back area Buttocks	White plaques++ Itching+	Previously took allopathic Rx & Homoeopathic treatment -No relief	
Hands-Elbow area since 4months			

Past History: In 2004-Operated for Right side inguinal Hernia

Family History:

Fa-78yrs,HTN+ Retd.Govt servant

Mo-68yrs,Chronic urticaria,House wife

Uncle(mama)-Psoriasis

Personal History:

Appearance: Tall,well built,neatly dressed,well behaved.

Wound healing: Normal


Perspiration: Scanty

Cravings: Meat+++ , Aversion: Nothing specific

Appetite:Good Stool: Normal Urine: Normal

Sleep: Good (7-8hrs) Dreams: Golf+

Thermals: Chilly (C3H2)



## Life space investigations:

Pt is born & brought up in kerala. Studied at Chennai. Family consists of Fa,Mo & 1 elder sister. Father reted as govt servant,Mother is house wife, elder sister is working in govt service. Pt had a happy childhood with good relations with everyone. Both parents were very co-operative Pt got married in 2004 to an HR manager of a software company. It was an arranged marriage. Pt present problems started after marriage. He once casually shared about his previous affair to his wife. Since then wife became suspicious on pt. She started checking his phone calls, started enquiring among pt colleagues,friends. She gradually started spreading rumors about patient badly to relatives and friends. Pt tried to convince her that he has no relation with her now. wife became more rude and more irritating to patient. wife started calling everyone at pt's family to tell about him. Patient became more frustrated with her. He kept quiet to maintain peace at home. Sometimes he felt that "why is it happening to me", I have not done anything wrong. I am wrongly accused. Things became worse and pt had to take a decision after waiting for 2yrs. In 2006 he applied for divorce. He got frustrated with all the allegations made by patient. with great difficulty in 2011 pt got divorced legally with her.Post divorce he is staying alone at Hyd and enjoys playing golf and kept pets for his company.

Physical examination:

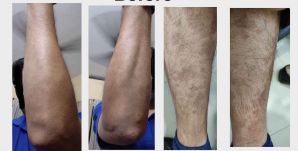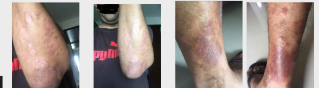wt:89kgs BP:110/80mmHg RS-clear CVS-S1S2-N

Local examination: erythematous patches with white scaling on Hands,Legs,back  
Auspitz sign+ve

Final Diagnosis: Psoriasis

Totality:

1. Ailments from anger suppressed
2. Ailments from indignation
3. Ailments from rudeness of others
4. Ailments from accusations
5. Delusion he is persecuted
6. craving for meat
7. Chilly



Repertorial result:

Staph-13/5

Nat.mur-9/5

Lyco-7/4

Final Prescription:

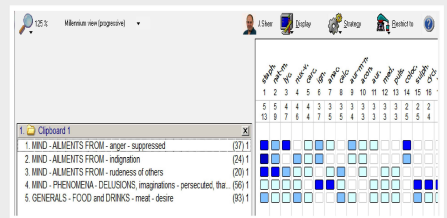
7/07/2017

Staph 200 weekly one dose

Follow up:

1/08/17	Scaling and lesions>>	SL for 1month
30/8/17 to 3/12/18	No new lesions appeared. Old patches disappeared Pt was better	Continued SL
3/1/19	New patches on elbow reappeared	Staph1M weekly dose
1/02/19 to 12/11/19	No new lesions appeared. Pt was better	Continued SL

Evidence: All photographs attached



Hamsa Homoeopathy Medical college,Hospital & research centre, Ksheerasagar (V) Mulugu(M),Telangana-502279